



Fertilità maschile: vecchie e nuove sfide in un ambiente a rischio



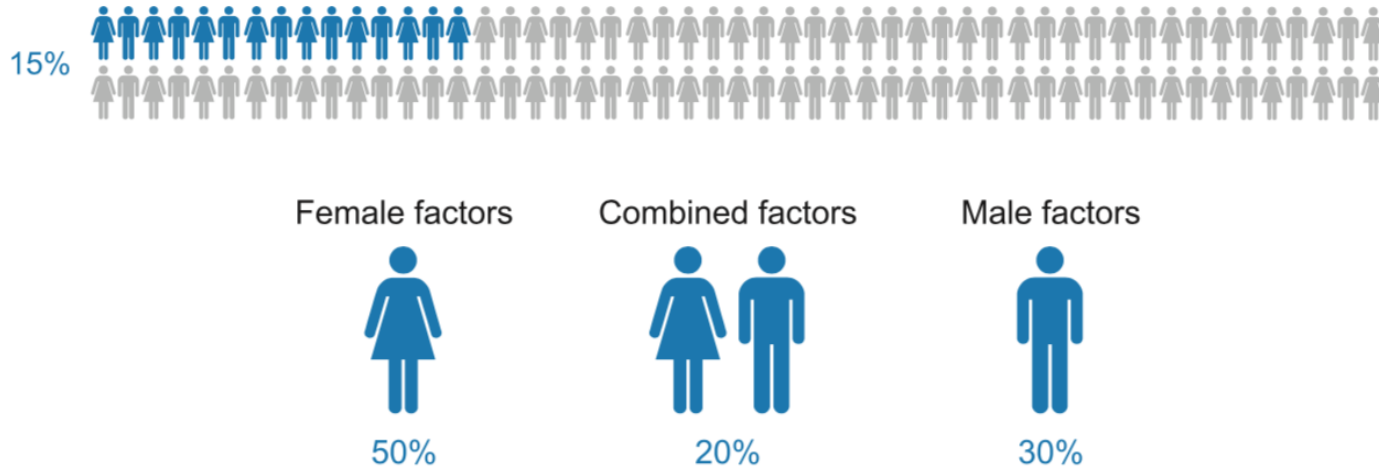
Dr. Luca Meggiato

Clinica Urologica
Azienda Ospedaliera Universitaria di Padova



INFERTILITA'

«assenza di concepimento spontaneo all'interno di una coppia sessualmente attiva dopo 12 mesi di rapporti mirati non protetti»



INFERTILITA' MASCHILE

- Idiopatica 30-40 % dei casi
- Associata a fattori specifici

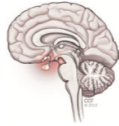Table 36: Male infertility causes and associated factors and percentage of distribution in 10,469 patients [1539]

Diagnosis	Unselected patients (n = 12,945)	Azoospermic patients (n = 1,446)
All	100%	11.2%
<i>Infertility of known (possible) cause</i>	42.6%	42.6%
Maldescended testes	8.4	17.2
Varicocele	14.8	10.9
Sperm auto-antibodies	3.9	-
Testicular tumour	1.2	2.8
Others	5.0	1.2
<i>Idiopathic infertility</i>	30.0	13.3
<i>Hypogonadism</i>	10.1	16.4
Klinefelter syndrome (47, XXY)	2.6	13.7
XX male	0.1	0.6
Primary hypogonadism of unknown cause	2.3	0.8
Secondary (hypogonadotropic) hypogonadism	1.6	1.9
Kallmann syndrome	0.3	0.5
Idiopathic hypogonadotropic hypogonadism	0.4	0.4
Residual after pituitary surgery	< 0.1	0.3
Late-onset hypogonadism	2.2	-
Constitutional delay of puberty	1.4	-
Others	0.8	0.8
<i>General/systemic disease</i>	2.2	0.5
<i>Cryopreservation due to malignant disease</i>	7.8	12.5
Testicular tumour	5.0	4.3
Lymphoma	1.5	4.6
Leukaemia	0.7	2.2
Sarcoma	0.6	0.9
<i>Disturbance of erection/ejaculation</i>	2.4	-
Obstruction	2.2	10.3
Vasectomy	0.9	5.3
Cystic fibrosis (congenital bilateral absence of vas deferens)	0.5	3.0
Others	0.8	1.9



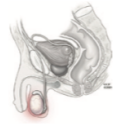INFERTILITA' MASCHILE

Pre-testicular



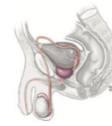- Hypothalamic disease:**
- Gonadotropin deficiency (Kallmann syndrome)
 - Isolated LH deficiency ("fertile eunuch")
 - Isolated FSH deficiency
 - Congenital hypogonadotropic syndromes
- Pituitary disease:**
- Pituitary insufficiency
 - Hyperprolactinemia
 - Exogenous hormones
 - Growth hormone deficiency

Testicular



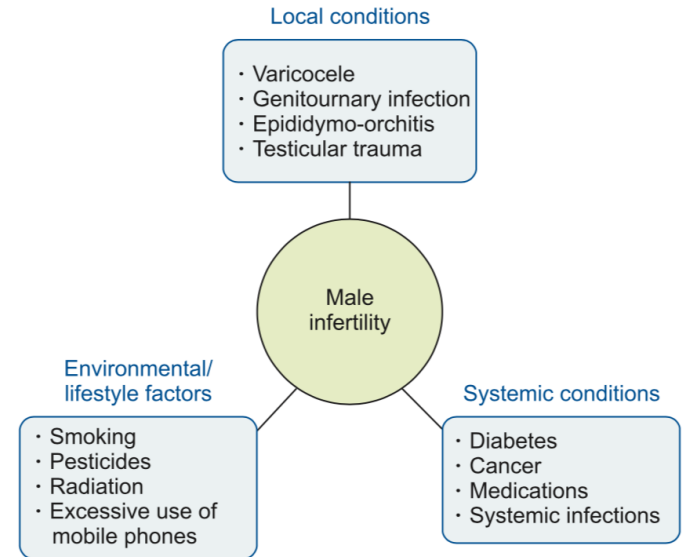
- Chromosomal:**
- Klinefelter syndrome
 - XX male (sex reversal syndrome)
 - XYY male
 - Others
- Non-chromosomal:**
- Varicocele
 - Cryptorchidism
 - Sertoli-cell-only syndrome
 - Chemo/radiotherapy
 - Others

Post-testicular



- Other causes:**
- Congenital blockage of the ductal system
 - Cystic fibrosis
 - Acquired blockage of the ductal system
 - Antisperm antibodies
 - Ejaculatory duct obstruction

Forme Idiopatiche



INFERTILITA' MASCHILE IDIOPATICA

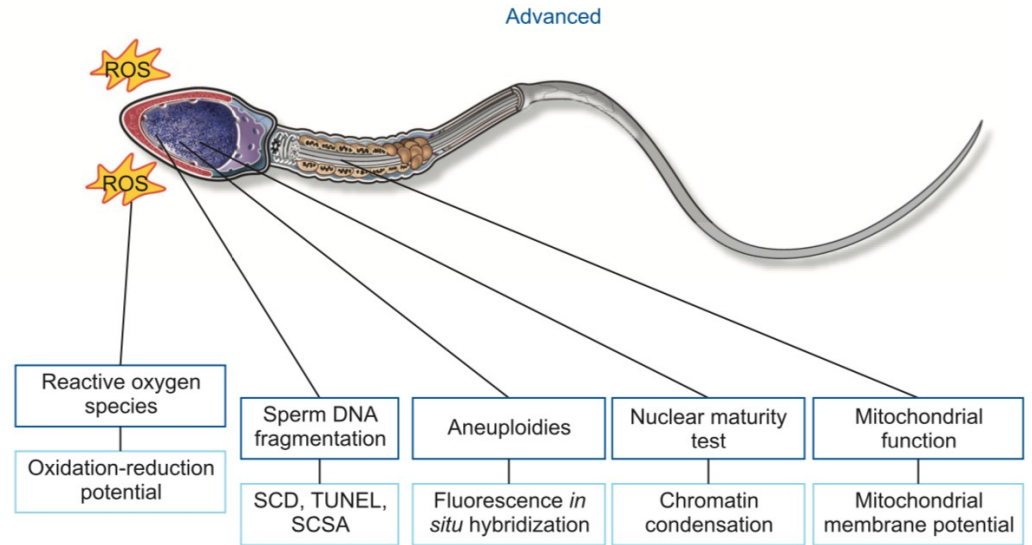
STRESS OSSIDATIVO



Frammentazione del DNA (DFI)
Aneuploidie

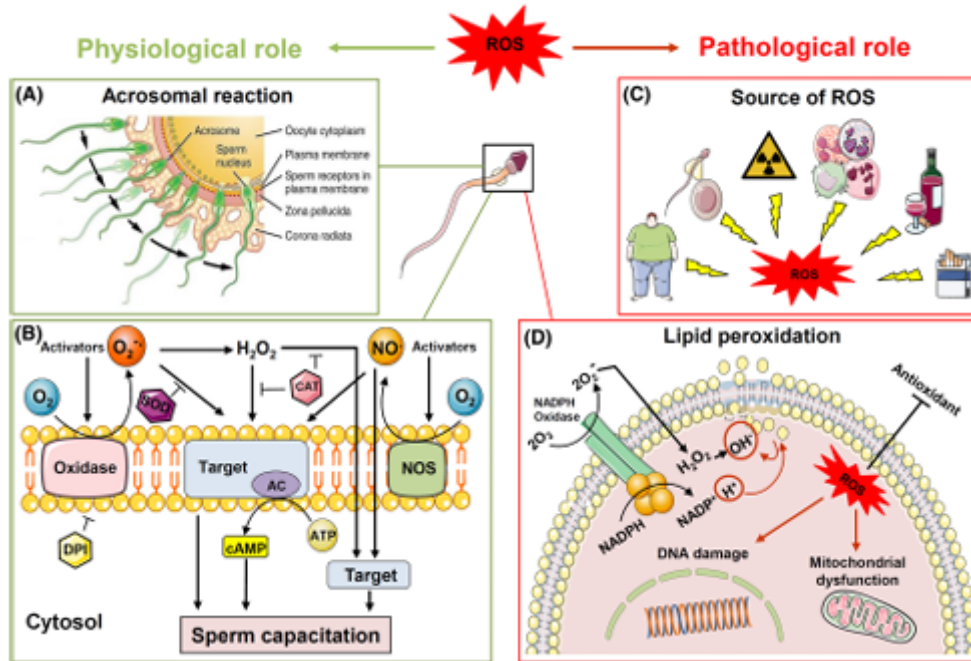


Indagini avanzate del liquido
seminale



Oxidative stress and male infertility: current knowledge of pathophysiology and role of antioxidant therapy in disease management

Erfaneh Barati¹ · Hossein Nikzad^{1,2} · Mohammad Karimian^{1,2} 

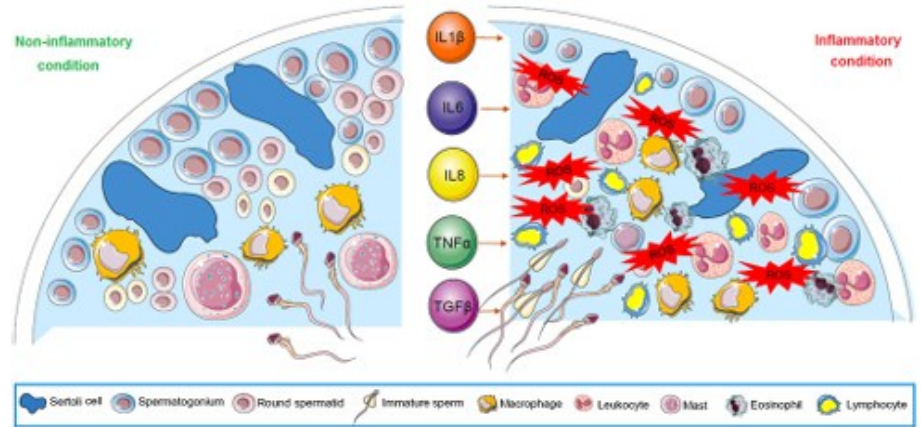
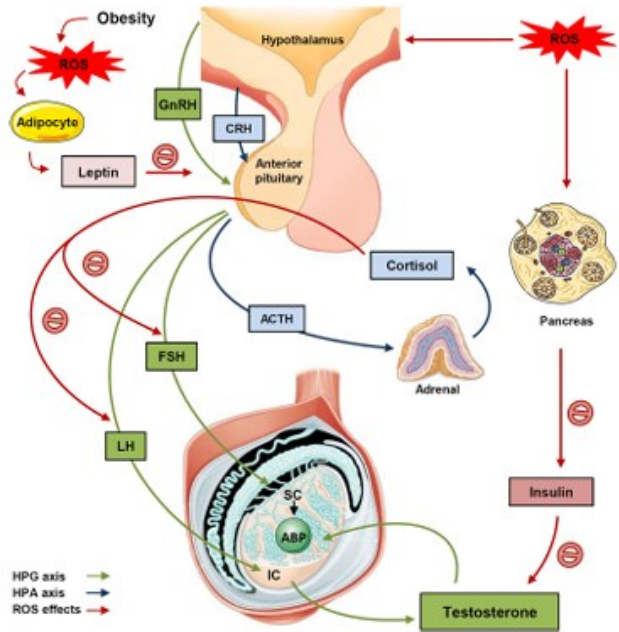


- Iperattivazione del flagello
- Capacitazione
- Reazione acrosomiale

- Perossidazione lipidica
- Danno DNA
- Disfunzione mitocondriale

Oxidative stress and male infertility: current knowledge of pathophysiology and role of antioxidant therapy in disease management

Erfaneh Barati¹ · Hossein Nikzad^{1,2} · Mohammad Karimian^{1,2}



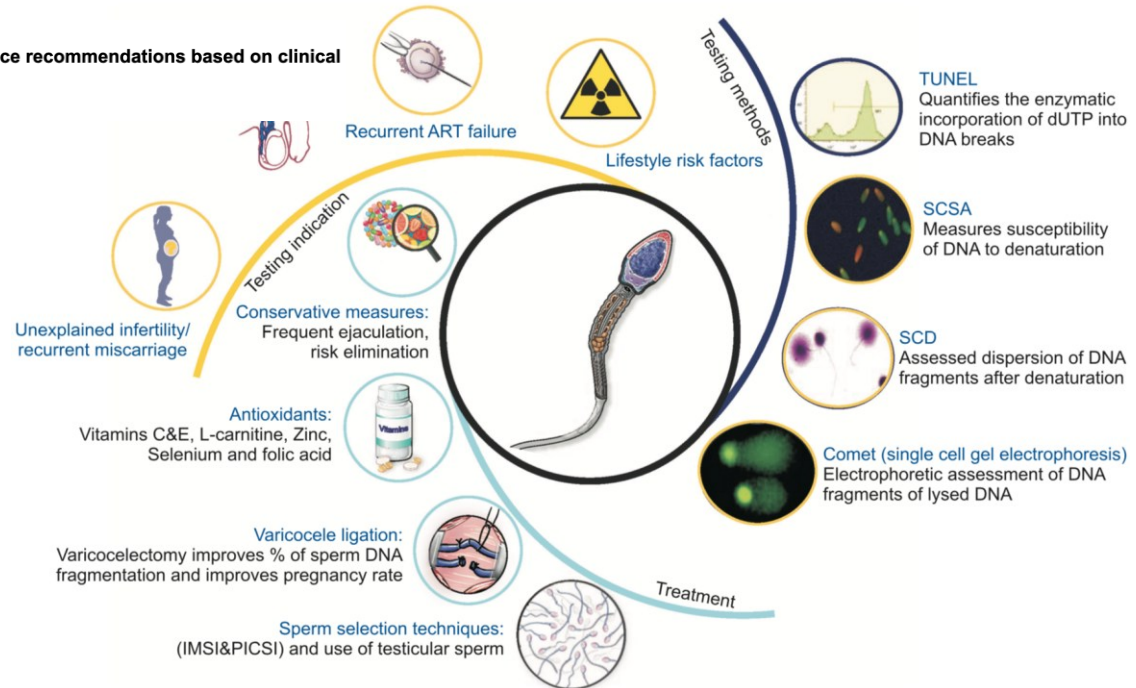
DIAGNOSI

Frammentazione del DNA

Transl Androl Urol. 2016 Dec;5(6):935-950. doi: 10.211037/tau.2016.10.03.

Clinical utility of sperm DNA fragmentation testing: practice recommendations based on clinical scenarios.

Agarwal A¹, Majzoub A², Esteves SC³, Ko E⁴, Ramasamy R⁵, Zini A⁶.



Lewis SE, John Aitken R, Conner SJ, Iulius GD, Evenson DP, Henkel R, et al. The impact of sperm DNA damage in assisted conception and beyond: recent advances in diagnosis and treatment. Reprod Biomed Online 2013;27:325-37.



DIAGNOSI

Profilo Ormonale

- Testosterone + FSH
- LH + Prolattina + estradiolo
(se ipotestosteronemia)

Da eseguirsi in caso di:

- Ridotta conta spermatica
- Ipogonadismo sintomatico/clinico
- Precedenti terapie ormonali

Indagini Genetiche

- Cariotipo
- Microdelezioni del cromosoma Y
- mutazione del gene CFTR (CBAVD e CUAVD)

aberrazioni cromosomiche rilevanti in:

- 5% degli uomini con infertilità
- 35% degli uomini azoospermici



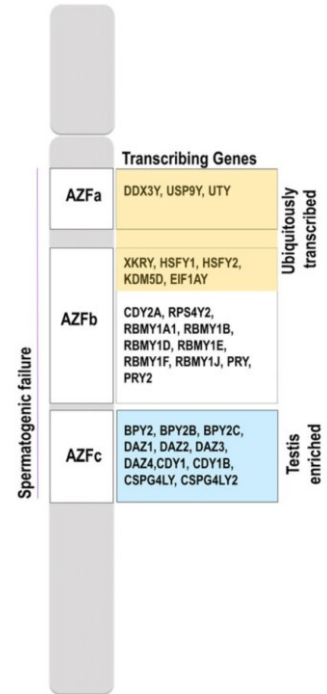
MICRODELEZIONI DEL CROMOSOMA Y

Azoospermia factor (AZF) Yq

- AZFa
- AZFb
- AZFc (prognosi migliore)

NON candidare i Pazienti con mutazioni AZF a-b-a/b a biopsia testicolare per l'elevato tasso di insuccesso nella ricerca di spermatozoi.

Indicato in caso di azoospermia NON ostruttiva

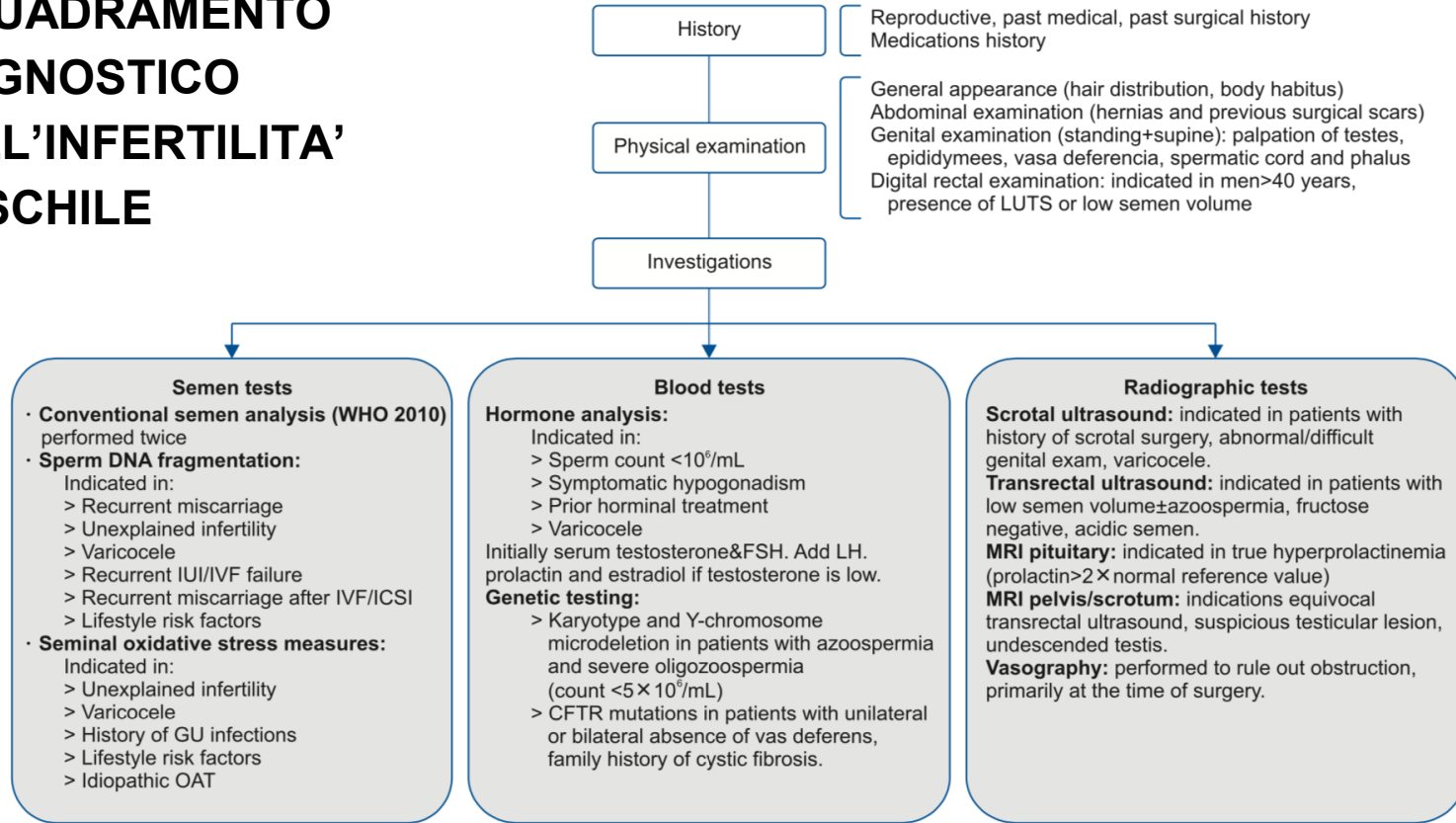


Goncalves C, Cunha M, Rocha E, Fernandes S, Silva J, Ferraz L, et al. Y-chromosome microdeletions in nonobstructive azoospermia and severe oligozoospermia. Asian J Androl 2017;19:338-45

Park SH, Lee HS, Choe JH, Lee JS, Seo JT. Success rate of microsurgical multiple testicular sperm extraction and sperm presence in the ejaculate in Korean men with y chromosome microdeletions. Korean J Urol 2013;54:536-40



INQUADRAMENTO DIAGNOSTICO DELL'INFERTILITA' MASCHILE



CRIPTORCHIDISMO – ECTOPIA TESTICOLARE

La più comune anomalia genitale maschile (1% dei maschi nati a termine)

Testicolo non palpabile nel 30% dei casi (possibile localizzazione addominale)

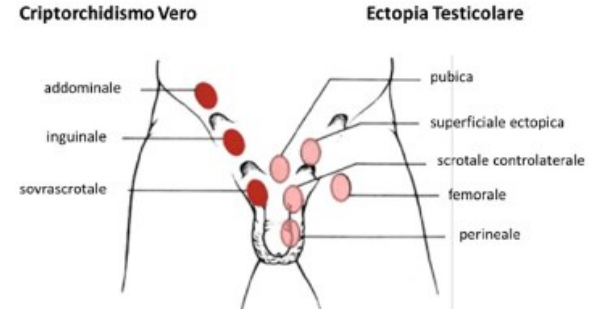
Classificazione in base a insorgenza e localizzazione testicolare:
congenita o acquisita
unilaterale o bilaterale
testicolo palpabile (inguinale) o non palpabile (addominale)

Correzione tra 6 e 18 mesi (mantenimento spermatogenesi, funzione endocrina e riduzione rischio neoplastico)

Trattamento chirurgico (orchidopessi) > trattamento endocrino (GnRH solo se bilaterale)

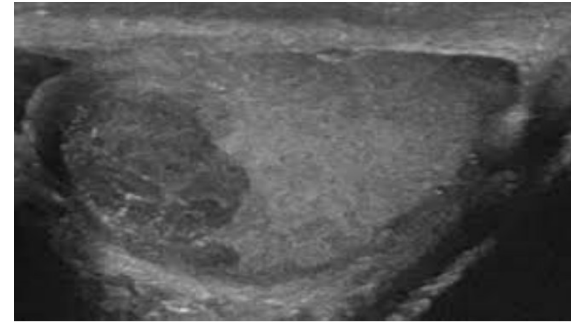
Anomalie strutturali e dimensionali anche nel testicolo disceso

Parte della sindrome da disgenesia testicolare (TDS) → esposizione a fattori di rischio durante la vita intrauterina

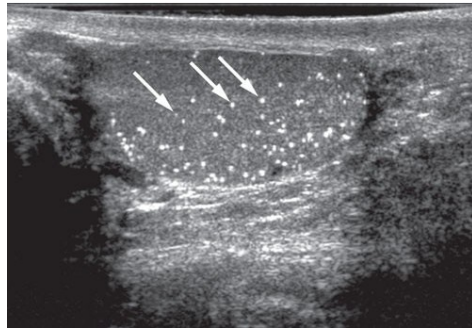


NEOPLASIE DEL TESTICOLO

- Neoplasia a maggior prevalenza in caucasici tra i 15 e i 40 anni
 - 1% dei Pazienti sub-fertili
 - Incidenza in aumento
 - Neoplasie germinali (TGCT) >>> non germinali (rare)
- Diagnosi:
- EO (autopalpazione), imaging, marcatori (β hCG, AFP, LDH), biopsia



ecografia scrotale (ECD, sonoelastografia)



Microcalcificazioni intratesticolari

- in condizioni benigne
- lesione premaligna
- correlazione con disgenesia testicolare
- rischio 18 volte maggiore di sviluppare TGCT in Pazienti infertili
- opportunità di biopsia testicolare se ad alto rischio di GCNIS

NEOPLASIE DEL TESTICOLO

Orchiectomia per neoplasia → compromissione della qualità del liquido seminale nel 50%

Disfunzione cellule di Leydig pre-trattamento anche in testicolo controlaterale → rischio ipogonadismo post-trattamento (max a 6-12 mesi); in caso di persistenza → terapia testosterone, gonadotropine o modulatori selettivi recettore estrogenico (SERMS)

CHT e RT → effetto teratogeno → contraccezione per almeno 6 mesi dopo il termine del trattamento

RT → raramente infertilità a lungo termine

CHT → infertilità dipendente dalla dose cumulativa (incremento aneuploidie fino a due anni dal termine della terapia e incremento SDF)

Criopreservazione del liquido seminale consigliabile prima di qualsiasi trattamento → eventuale onco-TESE (in corso di orchifuniculectomia)



NEOPLASIE DEL TESTICOLO

azoospermia in 24% e oligozoospermia in 50% dei Pazienti con TGCT **prima** del trattamento

Review

Male infertility and urological tumors: Pathogenesis and therapeutical implications

G Gulino , A Distante, A Akhundov and PF Bassi

UJ | Urologia
Journal

Urologia Journal
2023, Vol. 90(4) 622-630
© The Author(s) 2023



Article reuse guidelines:
sagepub.com/journals-permissions
DOI: 10.1177/03915603221146147
journals.sagepub.com/home/urj

 Sage

Meccanismi di compromissione del liquido seminale:

- Effetto volumetrico distruttivo della neoplasia sul parenchima sano
- Incremento temperatura testicolare per alterazione vascolarizzazione locale e neoangiogenesi
- Insorgenza maggiore in contesto di TDS
- Feedback negativo sull'asse ipotalamo-ipofisario ad opera delle gonadotropine secrete dalle cellule neoplastiche
- Alterazione barriera emato-testicolare → produzione di ASA e conseguente danno tissutale (73%)

- RPLND bilaterale/unilaterale, open, VLS, robotica, pre vs post CHT → retroejaculazione o anejaculazione
- Impatto sulla fertilità anche da parte di altre neoplasie genitourinarie (vescica-uretra, prostata, pene) → diagnosi e trattamento locale o a distanza sempre più precoce

Solo **24-30%** dei Pazienti con neoplasia del testicolo ricorrono alla criopreservazione

Protocolli terapeutici con GnRh analoghi e testosterone → **stato dormiente prepuberale** → riduzione effetto citotossico sugli spermatozoni (valutazione ipogonadismo post-operatorio)

Autotrapianto di cellule germinali



NEOPLASIE DEL TESTICOLO

World Journal of Urology (2022) 40:2293–2303
<https://doi.org/10.1007/s00345-022-04048-6>

ORIGINAL ARTICLE



Oncological and functional outcomes after testis-sparing surgery in patients with germ cell tumors: a systematic review of 285 cases

Josias Bastian Grogg¹ · Zeynep Hafza Dursun¹ · Joerg Beyer² · Daniel Eberli¹ · Cedric Poyet¹ · Thomas Hermanns¹ · Christian Daniel Fankhauser^{1,3}

Pazienti selezionati

Lesioni inferiori a 2 cm localizzate in sede polare

Ipogonadismo 27% (40% se adjRT)

Infertilità 18%

AdjRT riduce recidiva locale (2% vs 50%)

Metastasi a distanza nel 2%

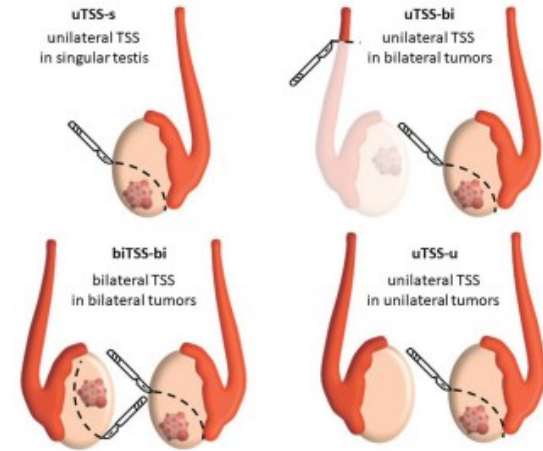
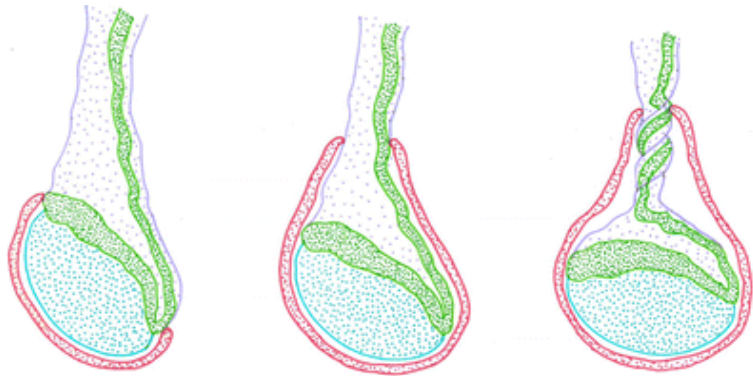


Fig. 1 Grouping of patients undergoing TSS for testicular GCT based on the clinical scenario



TORSIONE DEL TESTICOLO

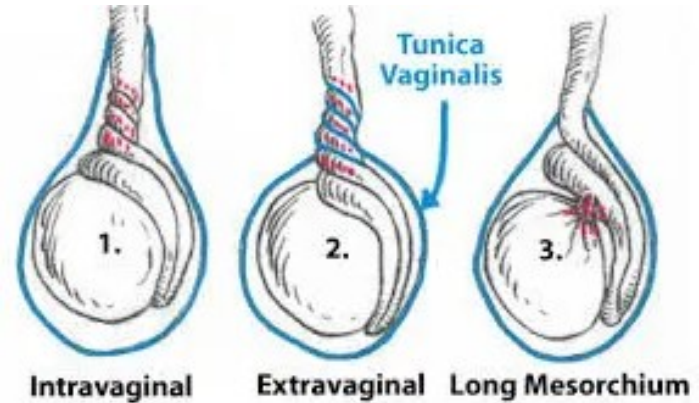
Anomala inserzione della tunica vaginale



Normal

Bell-clapper anomaly

Intravaginal torsion



Intravaginal

Extravaginal

Long Mesorchium

TORSIONE DEL TESTICOLO

DOI: 10.1016/j.emc.2011.04.011 • Corpus ID: 2818047

Scrotal emergencies.

Jonathan E. Davis, M. Silverman • Published in *Emergency medicine clinics of...* 2011 • Medicine

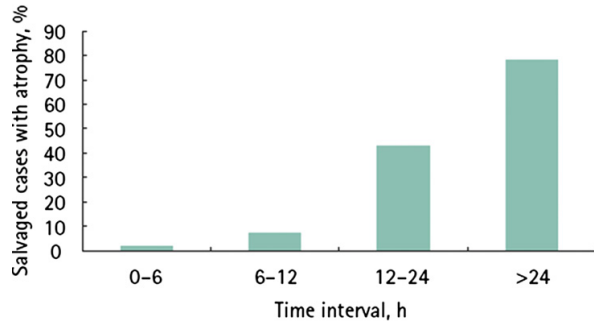
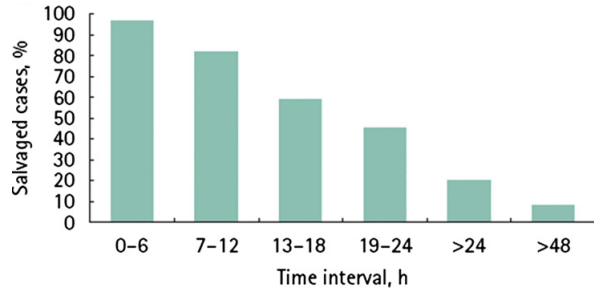
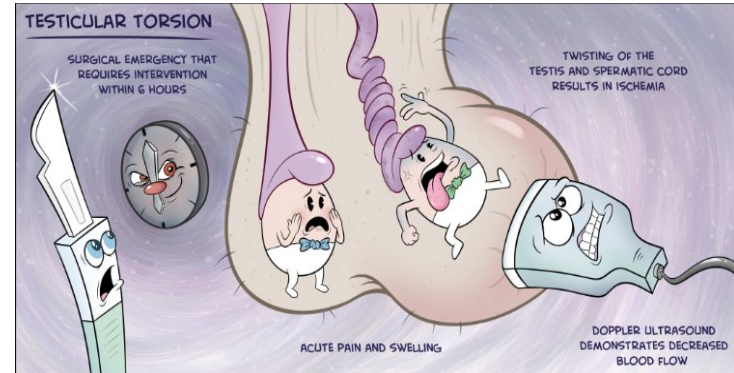


Table 3

Scrotal trauma

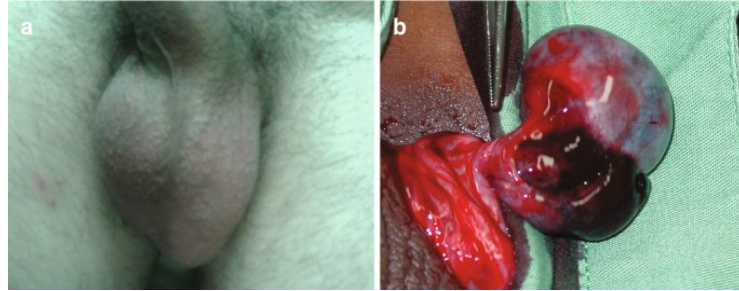
Condition	Etiology, Presentation	Treatment
Testicular dislocation	Significant blunt-force mechanism (dislocation to the abdomen or to subcutaneous tissues surrounding the external inguinal ring)	Surgical intervention
Testicular rupture	Disruption of the tunica albuginea	Surgical intervention
Testicular contusion	Intratesticular hematoma; intact tunica albuginea	Typically conservative: ice, rest, elevation
Hematocele	Blood accumulation in the tunica vaginalis	Surgical drainage for large hematocele; conservative otherwise
Penetrating injury	Varies depending on cause	Typically surgical exploration/intervention
Traumatic testicular torsion	Traumatically induced torsion has been reported	Surgical exploration/intervention



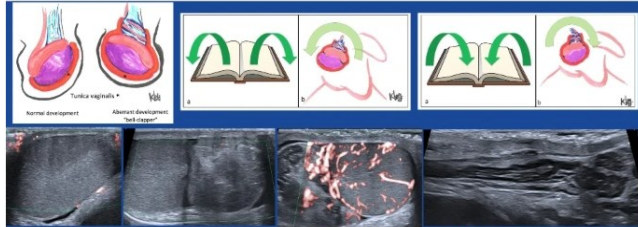
TORSIONE DEL TESTICOLO

Acute scrotum: differential diagnosis

	<i>Testicular torsion</i>	<i>Torsion of the testicular appendage</i>	<i>Epididymo-orchitis</i>
Age	– Neonatal – Postpubertal	– Prepubertal	– Post/prepubertal
Evolution	– Acute	– Subacute	– Subacute
Pain and location	– Diffuse	– Upper pole of testicle	– Epididymis
Cremasteric reflex	– Absent	– Present	– Present
Other findings	– General condition impairment	– “Blue dot”	– Fever – Urinary symptoms – Sexual activity +



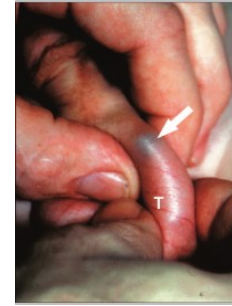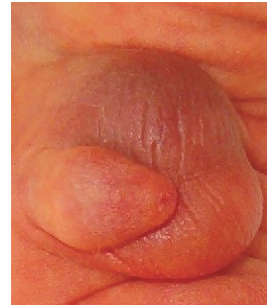Testicular torsion and ultrasound-assisted manual detorsion



US-assisted manual testicular detorsion is a non-invasive, simple, quick, safe, and effective manoeuvre that can rapidly restore blood flow, maximizing testicular salvage, relieving patient's symptoms, and facilitating surgery

Pediatric Radiology

Jose L. Vazquez et al



Derotazione manuale o esplorazione chirurgica



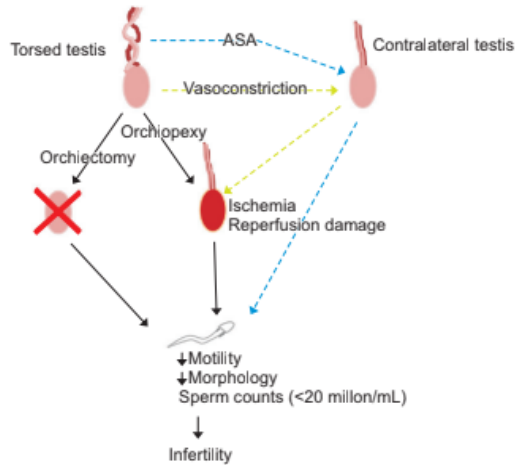
TORSIONE DEL TESTICOLO

The Impact of Testicular Torsion on Testicular Function

Frederik M. Jacobsen¹, Trine M. Rudlang¹, Mikkel Fode¹, Peter B. Østergren¹, Jens Sønkens¹, Dana A. Ohl², Christian Fuglesang S. Jensen³; On behalf of the CopMich Collaborative

¹Department of Urology, Herlev and Gentofte Hospital, University of Copenhagen, Herlev, Denmark, ²Department of Urology, University of Michigan, Ann Arbor, MI, USA

- nessuna compromissione funzione endocrina testicolare
- riduzione conta e motilità spermatica correla con durata ed entità della torsione
- il salvataggio della gonade non esclude la compromissione del liquido seminale



possibile compromissione spermatogenesi testicolo controlaterale (3 ipotesi patogenetiche):

- danno da rivascolarizzazione del testicolo torto → vasocostrizione riflessa mediata dall'ortosimpatico inducendo ipossia al testicolo controlaterale
- rottura della barriera emato-testicolare indotta dalla torsione → reazione immunitaria con produzione di ASA
- coesistenza di TDS pre-esistente



TRAUMI E COMPLICANZE/CONSEGUENZE CHIRURGICHE

Korean J Urol. 2007 Jan;48(1):61-65. English.
Published online Jan 31, 2007.
<https://doi.org/10.4111/kju.2007.48.1.61>
Copyright © 2007 The Korean Urological Association

Original Article

Testicular Injuries-Efficacy of the Organ Injury Scale Developed by the American Association for the Surgery of Trauma

Jung-Suk Park,¹ and Sun-Ju Lee²

Table 1.

Testis grade according to the American Association for the Surgery of Trauma (AAST) organ injury severity scale

Grade	Description
I	Contusion/hematoma
II	Subclinical laceration of the tunica albuginea
III	Laceration of the tunica albuginea with less than 50% parenchymal loss
IV	Major laceration of the tunica albuginea with 50% or greater parenchymal loss
V	Total testicular destruction or avulsion

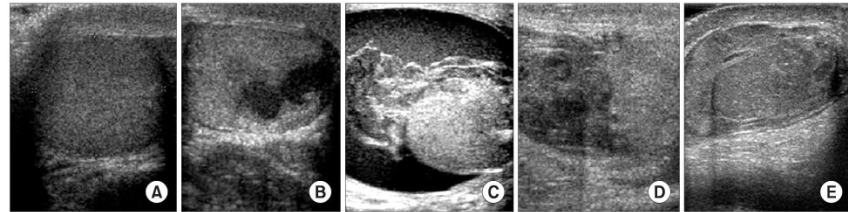


Fig. 1.

Testis injury, American Association for the Surgery of Trauma Organ Injury Scaling. (A) Grade I, (B) Grade II, (C) Grade III, (D) Grade IV and (E) Grade V.

- danno diretto parenchima testicolare
- ematoma → compressione parenchimale e vascolare → ipossia
- rottura barriera emato-testicolare → produzione ASA
- lesione/ostruzione vie spermatiche
- se non gestibili conservativamente → chirurgia conservativa o orchietomia (conseguenze su conta e motilità spermatica)



TRAUMI E COMPLICANZE/CONSEGUENZE CHIRURGICHE

Ernioplastica inguinale
Varicocelectomia
Eversione tunica vaginale
Asportazione spermatoceeli
Orchifuniculectomia
Vasectomia
Procedura urologiche
endoscopiche



Lesioni vascolari
Compressione prencimale/vascolare
Infezioni
Lesione/ostruzione sbocco dotti eiaculatori
Lesione/ostruzione dotto deferente

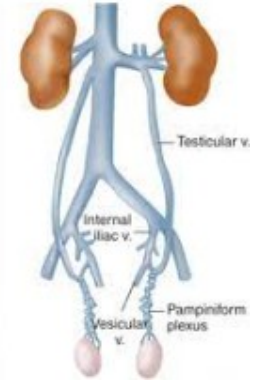
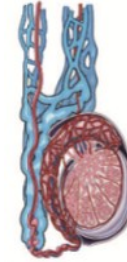Definition	
Grade I	any deviation from the ordinary post-operative course without giving pharmacological and surgical interventions.
Grade II	complication requires pharmacological treatment
Grade IIIa	complication requires surgical intervention under local anesthesia
Grade IIIb	complications requires surgical intervention under general anesthesia
Grade IV	complications are related to life-threatening complications that require intensive care unit management
Grade V	complications are related to patient's death.

Classificazione di
Clavien-Dindo



Varicocele

- 15% dei maschi
- 25% dei maschi con alterazioni del liquido seminale
- 11% dei maschi azoospermici



Fisiopatologia
non chiaramente
definita



Beneficio associato
al trattamento

- Produzione ROS
- Aumento temperatura scrotale
- Ristagno metaboliti



Varicocele

Urology. 2007 Sep;70(3):532-8.

Efficacy of varicoelelectomy in improving semen parameters: new meta-analytical approach.

Agarwal A¹, Deepinder F, Cocuzza M, Agarwal R, Short RA, Sabanegh E, Marmar JL.

Asian J Androl. 2016 Mar-Apr;18(2):186-93. doi: 10.4103/1008-682X.170441.

Novel insights into the pathophysiology of varicocele and its association with reactive oxygen species and sperm DNA fragmentation.

Cho CL, Esteves SC, Agarwal A¹.

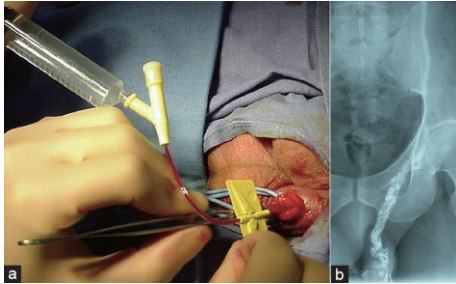
Curr Urol Rep. 2018 May 17;19(7):53. doi: 10.1007/s11934-018-0798-8.

The Effect of Subclinical Varicocele on Pregnancy Rates and Semen Parameters: a Systematic Review and Meta-Analysis.

Kohn TP¹, Ohlander SJ², Jacob JS¹, Griffin TM³, Lipshultz LI^{4,5}, Pastuszak AW^{6,7,8}.

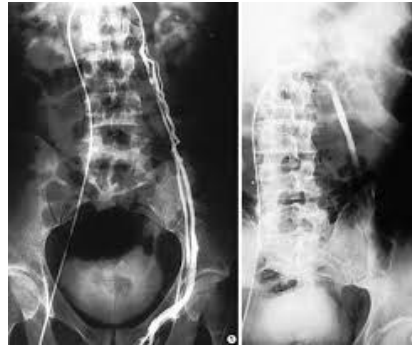

Sclerotizzazione anterograda sec Tauber



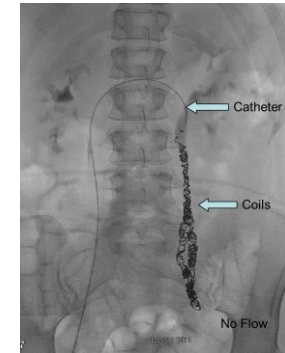
- Tasso di recidiva 9%
 - Tasso di complicanze del 0.5-2%:
 - Atrofia testicolare
 - epididimite
- Ischemia colica → flebografia!!!

Sclerotizzazione retrograda percutanea



- Tasso di recidiva 9.8%
- complicanze:
 - tromboflebite
 - danno vascolare
 - dolore al fianco

Embolizzazione retrograda percutanea

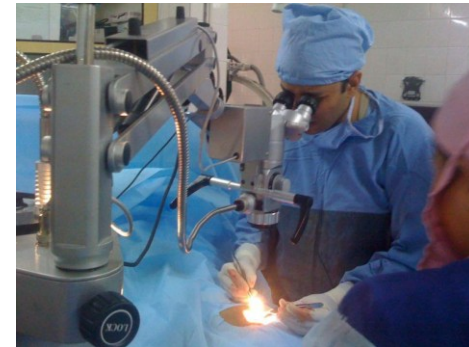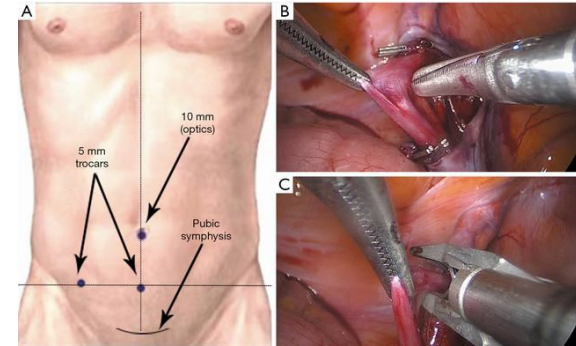


- Tasso di recidiva 4-10%
- complicanze:
 - tromboflebite
 - danno vascolare
 - emorragia retroperitoneale
 - dislocazione dei coil
 - ostruzione ureterale



Trattamento chirurgico del varicocele

- **Approccio inguinale**
 - tasso di recidiva 13%
 - elevato rischio di idrocele post-operatorio
- **Approccio laparoscopico**
 - tasso di recidiva 3-7%
 - procedura invasiva
 - possibile danno testicolare da devascularizzazione
- **Approccio inguinale microchirurgico**
 - tasso di recidiva 0.8 – 4%
 - minor rischio di idrocele post-operatorio



Marmar JL, Kim Y. Subinguinal microsurgical varicocelectomy: a technical critique and statistical analysis of semen and pregnancy data. J Urol 1994

Tan, S.M., et al. Laparoscopic varicocelectomy: technique and results. Br J Urol, 1995. 75: 523.

Trattamento chirurgico del varicocele

- Scleroembolizzazione anterograda sec. Tauber
- Scleroembolizzazione retrograda percutanea angiografica
- Embolizzazione retrograda angiografica
- Legatura scrotale vena spermatica sec. Ivanissevich
- Legatura inguinale vena spermatica sec. Palomo
- Legatura e sezione microchirurgica
- Legatura e sezione laparoscopica/robotica (comparabile a microchirurgia)

Table 38: Recurrence and complication rates associated with treatments for varicocele

Treatment	Recurrence/ Persistence %	Overall complications	Specific Complications
Antegrade sclerotherapy [1757, 1758]	5-9	Hydrocele (5.5%), haematoma, infection, scrotal pain, testicular atrophy, epididymitis	Technical failure 1-9%, left-flank erythema
Retrograde sclerotherapy [1759, 1760]	6-9.8	Hydrocele (3.3%) wound infection, scrotal pain	Technical failure 6-7.5%, adverse reaction to contrast medium, flank pain, persistent thrombophlebitis, venous perforation
Retrograde embolization [1759, 1761]	3-11	Hydrocele (10%) haematoma, wound infection	Technical failure 7-27%, pain due to thrombophlebitis, radiological complications (e.g., reaction to contrast media), misplacement or migration of coils (to femoral vein or right atrium), retroperitoneal haemorrhage, fibrosis, ureteric obstruction, venous perforation
<i>Open operation</i>			
Scrotal operation	-	Testicular atrophy, arterial damage with risk of devascularisation and testicular gangrene, scrotal haematoma, post-operative hydrocele	
Inguinal approach [1762, 1763]	2.6-13	Hydrocele (7.3%), testicular atrophy, epididymo-orchitis, wound complications	Post-operative pain due to incision of external oblique fascia, genitofemoral nerve damage
Open retroperitoneal high ligation [1751, 1764]	15-29	Hydrocele (5-10%), testicular atrophy, scrotal oedema	External spermatic vein ligation failure
Microsurgical inguinal or Subinguinal [1752, 1762, 1765, 1766]	0.4	Hydrocele (0.44%), scrotal haematoma	
Laparoscopy [1724, 1751, 1752, 1767, 1768]	3-6	Hydrocele (7-43%) epididymitis, wound infection, testicular atrophy due to injury of testicular artery, bleeding	External spermatic vein ligation failure, intestinal, vascular and nerve damage; pulmonary embolism; pneumo-scrotum; peritonitis; post-operative pain in right shoulder (due to diaphragmatic stretching during pneumo-peritoneum)



INFEZIONI GENITOURINARIE

Uretriti

Orchiti

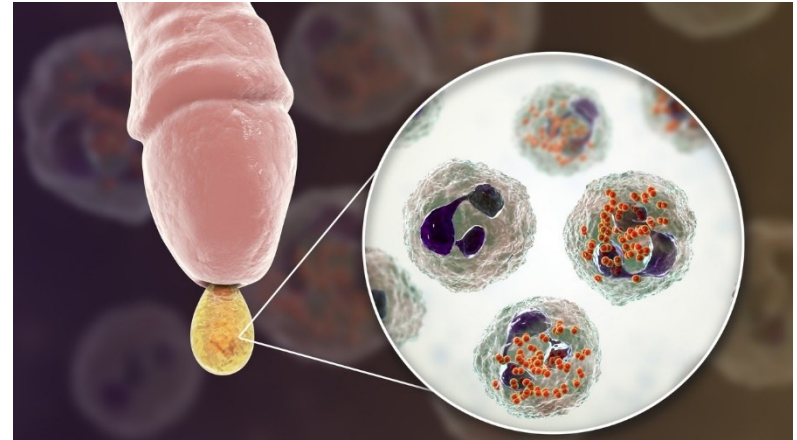
Prostatiti

Epididimiti

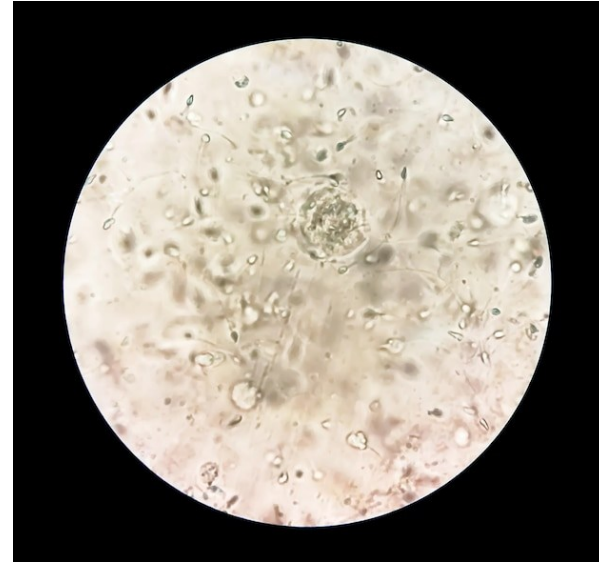
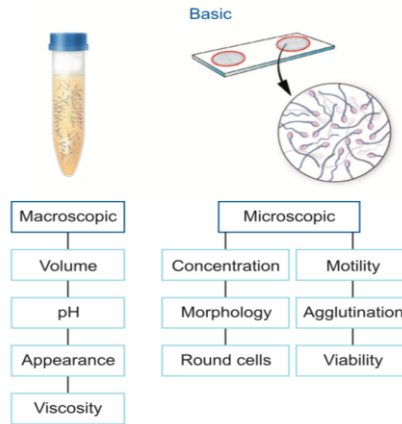


Danno tissutale
Stress ossidativo
ASA

Sequela a distanza (ostruzione vie spermatiche)



INFEZIONI GENITOURINARIE



Spermiogramma

Esame liquido seminale

WBC $> 10^6/\text{ml}$ = leucocitospermia \rightarrow infiammazione non necessariamente correlata a infezione (*valutare opportunità di trattamento*)

WBC perossidasi positivi ($>10^6/\text{ml}$) = infiammazione (conferma in caso di leucocitospermia)

Elastasi = presenza di polimorfonucleati funzionalmente attivi

Batteri $>10^3$ CFU/ml = batteriospermia

Alterati pH, acido citrico, gamma-glutamintranspeptidasi (disfunzione secrezione ghiandolare)



INFEZIONI GENITOURINARIE

Spermiocoltura

U. urealyticum, M. Hominis, C. trachomatis → prostatite cronica → infertilità (ASA, ROS, SDF)

HPV (10-35,7% pz infertili vs 2-31% popolazione generale), HSV-2 → infertilità

U. Parvum, M. Genitalium → non associati a infertilità (*valutare opportunità di trattamento*),

C. trachomatis, N. Gonorrhoea → epididimite sessualmente trasmessa (spesso associate a uretrite ≠ epididimite associata a infezioni urinarie)

PCR

Prostata: principale sede di origine delle citochine infiammatorie (soprattutto IL-6 e IL-8) mediatrici nelle MAGIs

Categoria	Tipo I	Tipo II	Tipo IIIA	Tipo IIIB	Tipo IV
Definizione	Prostatiti batteriche acute	Prostatiti batteriche croniche	Prostatiti abatteriche croniche / Sindrome del dolore pelvico cronico (CPPS)	Prostatiti batteriche croniche / sindrome del dolore pelvico cronico (CPPS)	Prostatiti infiammatorie asintomatiche
			Infiammatorie	Non Infiammatorie	

Classificazione National Institute of Health (NIH) delle prostatiti



INFEZIONI GENITOURINARIE

frontiers | Frontiers in Immunology

TYPE Review
PUBLISHED 21 February 2023
DOI 10.3389/fimmu.2023.1139450

Microbiology and immune mechanisms associated with male infertility

Jin Chen¹, Jinyu Chen², Yiwei Fang¹, Qiuzi Shen¹, Kai Zhao¹, Chunyan Liu¹ and Huiping Zhang^{1*}

¹Institute of Reproductive Health, Tongji Medical College, Huazhong University of Science and Technology, Wuhan, China, ²Department of Urology, Union Hospital, Tongji Medical College, Huazhong University of Science and Technology, Wuhan, China

- alterazioni microbiologiche associate all'infertilità maschile (eziologia)
- come i microorganismi influiscono sulla normale funzione del sistema riproduttivo maschile attraverso meccanismi immunitari
- collegamento tra microbioma e risposta immunitaria → individuazione di una attivazione immunitaria mediata da microorganismi anche in condizioni prive di carattere infettivo (es: varicocele)
- possibilità di individuare una terapia immunologica mirata eventualmente associata a terapia microbiologica

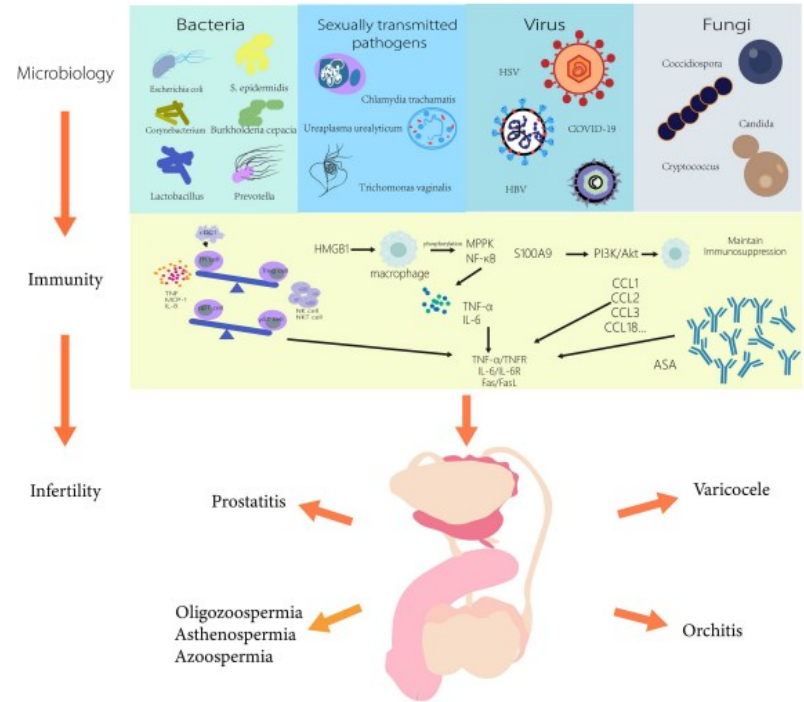


FIGURE 1
Microbiology and immune mechanisms associated with male infertility.



INFEZIONI GENITOURINARIE

Leukocytospermia and/or Bacteriospermia: Impact on Male Infertility

Ralf Henkel ^{1,2,3}

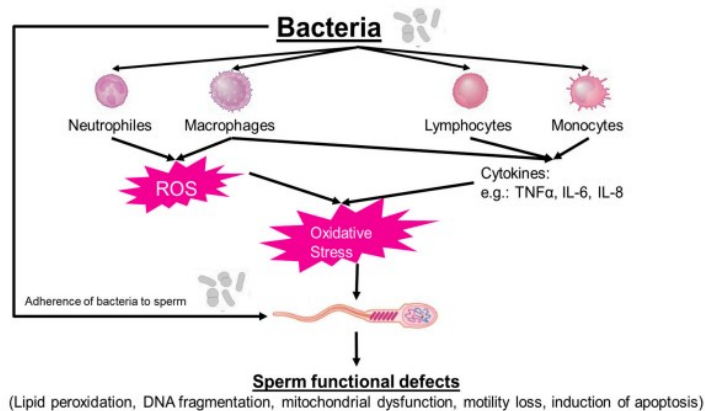
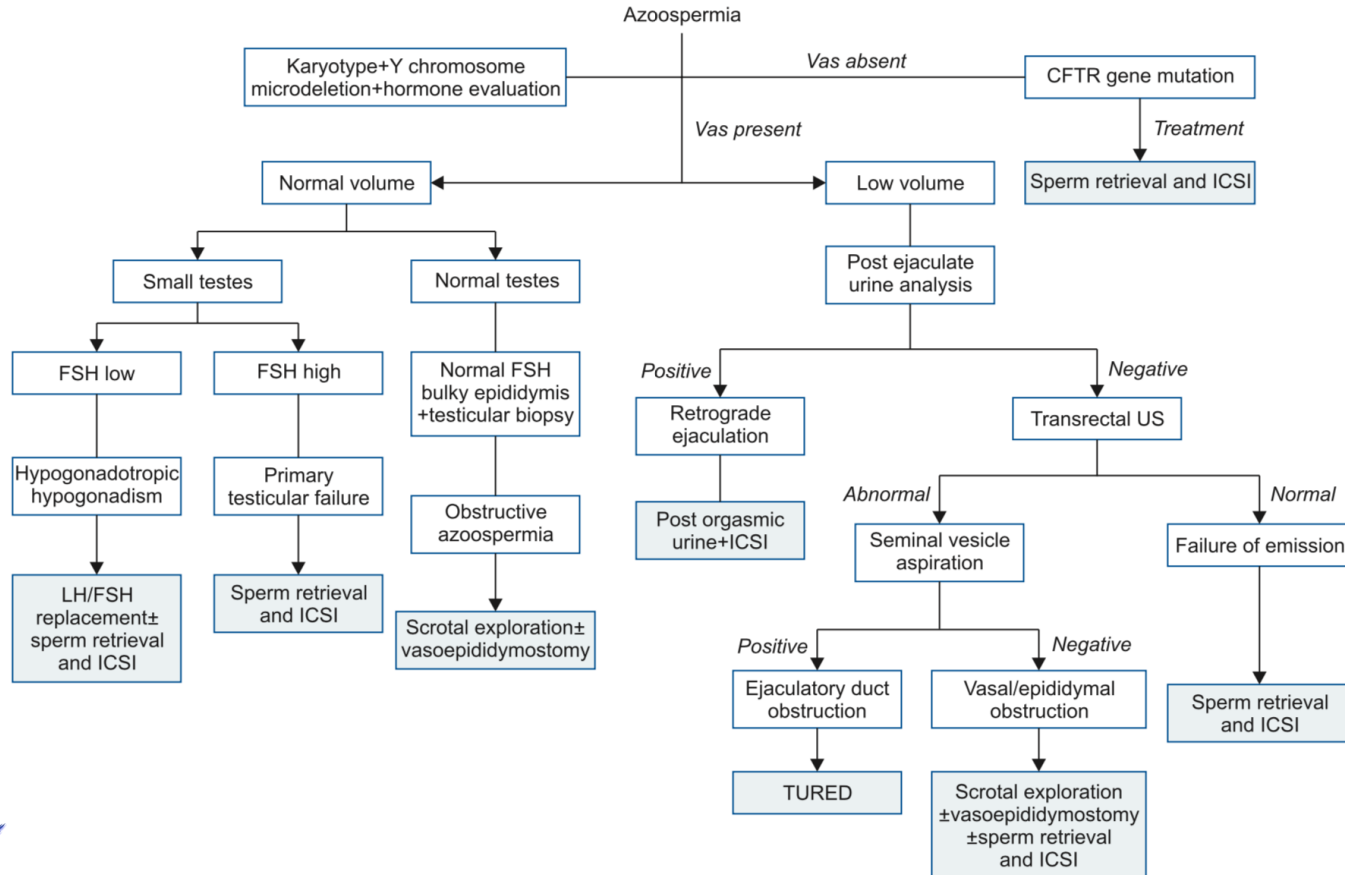


Figure 1. Direct and indirect effects of bacteria on sperm function.

- Innesco processo infiammatorio → ROS
- Adesione (pili, biofilm) → riduzione motilità spermatozoi
- Secrezione sostanze tossiche (LPS, emolisine, quorum sensing proteins)

- Meno di 10^6 WBC perossidasi+ nel liquido seminale fisiologia → rimozione spermatozoi disfunzionali o non vitali e ruolo in immunosorveglianza
- Leucocitospermia in 30% dei soggetti infertili, in 80% di questi in assenza di infezione
- Lattobacilli → effetto positivo su motilità e vitalità spermatica + riduzione perossidazione lipidica attraverso secrezione antiossidanti solubili
- Altre specie batteriche probiotiche → incremento peso testicolare e concentrazione FSH, LH e testosterone
- Epididimiti acute peggiori di prostatiti croniche → 10% azoospermia e 30% oligozoospermia conseguenti
- Necessaria distinzione in batteri con effetti benefici e batteri patogeni (valutare quando condurre terapia antibiotica in presenza di bacteriospermia)

TRATTAMENTO



CAUSE OSTRUTTIVE

Table 39: Causes of obstruction of the genitourinary system

Intratesticular (15%)
Epididymis (30-67%)
Infection (acute/chronic epididymitis)
Trauma
Post-surgical iatrogenic obstruction (i.e., MESA, hydrocelectomy or other scrotal surgery)
Congenital epididymal obstruction (usually manifests as congenital bilateral absence of the vas deferens [CBAVD])
Other congenital forms of epididymal obstruction (Young's syndrome)
Vas deferens
Vasectomy
Vasotomy/vasography (with improper technique)
Post-surgical iatrogenic obstruction (i.e., scrotal surgery or herniorrhaphy)
Congenital unilateral (CUAVD) or bilateral absence of the vas deferens (CBAVD)
Ejaculatory ducts
Cysts (Mullerian utricular, prostatic or seminal vesicular)
Infection (acute/chronic epididymitis)
Traumatic
Postsurgical iatrogenic obstruction
Functional obstruction
Idiopathic/acquired local neurogenic dysfunction

Ipoposia/aneiaculazione
Turgore epididimo

- Problematiche intrinseche (congenite/acquisite)
- Compressioni ab estrinseco (congenite/acquisite)
- Assenza /anomala maturazione embriologica



PRELIEVO CHIRURGICO DEGLI SPERMATOZOI

J In Vitro Fert Embryo Transf. 1985 Sep;2(3):119-22.

Human pregnancy by in vitro fertilization (IVF) using sperm aspirated from the epididymis.

Temple-Smith PD, Southwick GJ, Yates CA, Trounson AO, de Kretser DM.

Pietra miliare del trattamento dell'infertilità maschile che ha significativamente modificato la qualità dei Pazienti che altrimenti sarebbero stati definiti sterili.

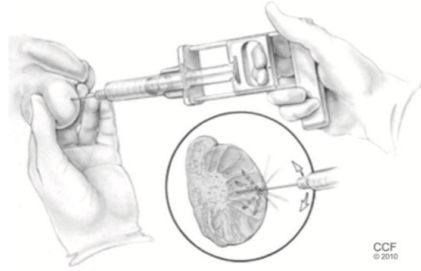


Goncalves C, Cunha M, Rocha E, Fernandes S, Silva J, Ferraz L, et al. Y-chromosome microdeletions in nonobstructive azoospermia and severe oligozoospermia. *Asian J Androl* 2017;19:338-45

Park SH, Lee HS, Choe JH, Lee JS, Seo JT. Success rate of microsurgical multiple testicular sperm extraction and sperm presence in the ejaculate in Korean men with y chromosome microdeletions. *Korean J Urol* 2013;54:536-40



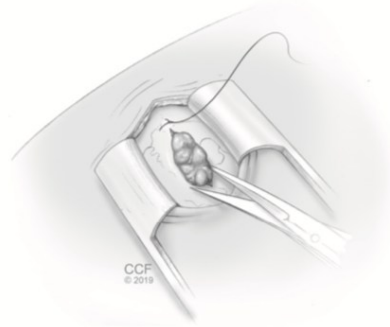
AZOOSPERMIA NON OSTRUTTIVA (TESA – TESE – micro TESE)



Testicular sperm aspiration

- Semplice e veloce
- Maggiore rischio di sanguinamento

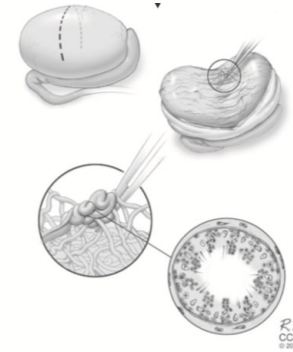
Tasso di successo
10-20%



Testicular sperm extraction

- Campione biologico maggiore/multiplo
- Maggiore rischio di danno parenchimale

Tasso di successo
25-50%



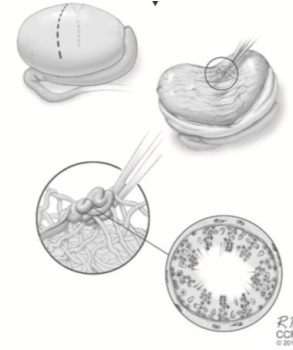
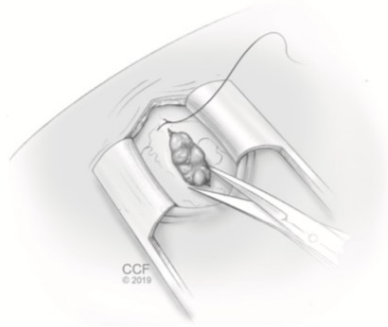
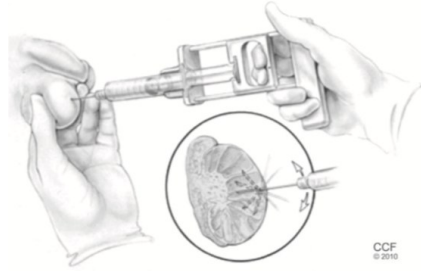
Microscopic testicular sperm extraction

- Biopsia dei singoli tubuli
- Minore danno parenchimale

Tasso di successo
35-77%



TESA – TESE – micro TESE



«pre-treatment with hormonal therapies can positively affect the surgical sperm retrieval outcome»

Andrology. 2013 Sep;1(5):749-57. doi: 10.1111/j.2047-2927.2013.00107.x.

Revisiting oestrogen antagonists (clomiphene or tamoxifen) as medical empiric therapy for idiopathic male infertility: a meta-analysis.

Chua ME¹, Escusa KG, Luna S, Tapia LC, Dofitas B, Morales M.

Hum Reprod. 2012 Feb;27(2):331-9. doi: 10.1093/humrep/der404. Epub 2011 Nov 28.

Human chorionic gonadotrophin treatment prior to microdissection testicular sperm extraction in non-obstructive azoospermia.

Shiraishi K¹, Ohmi C, Shimabukuro T, Matsuyama H.



AFFINAMENTO DELLA TECNICA E PROSPETTIVE FUTURE

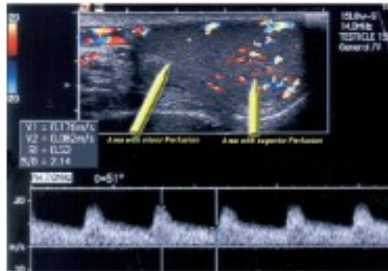
Tissue perfusion-controlled guided biopsies are essential for the outcome of testicular sperm extraction

Ralf Herwig, M.D.,^a Kadir Tosun, M.D.,^b Antonius Schuster, M.D.,^c Peter Rehder, M.D.,^b
Bernhard Glodny, M.D.,^d Ludwig Wildt, M.D.,^e Kari Ilmensee, Ph.D.,^c
and Germar-Michael Pinggera, M.D.^b

Fertility and Sterility® Vol. 87, No. 5, May 2007

FIGURE 1

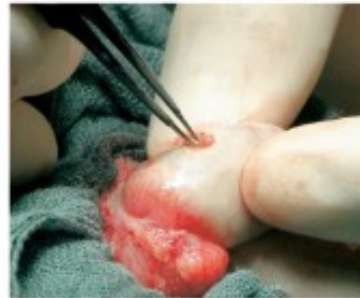Contrast-enhanced color Doppler ultrasound of left testicle of patient 5. Arrows indicate areas of major and minor perfusion.



Herwig. Testicle perfusion predicts sperm quality and quantity. Fertil Steril 2007.

FIGURE 3

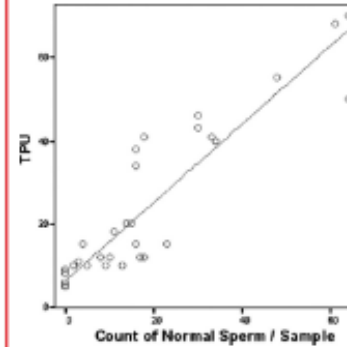
Small testicle of patient 5. A small incision was made to extract small parts of testicular tissue.



Herwig. Testicle perfusion predicts sperm quality and quantity. Fertil Steril 2007.

FIGURE 4

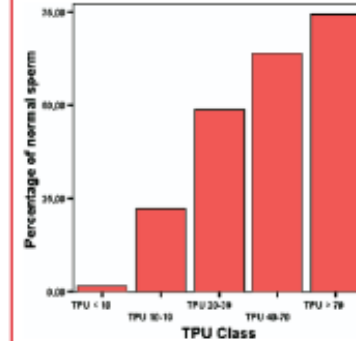
Correlation between TPU and count of normal sperm per 100 μ L. Each circle represents data from one particular TESE.



Herwig. Testicle perfusion predicts sperm quality and quantity. Fertil Steril 2007.

FIGURE 5

Percentage of normal sperm count in relation to TPU.



Herwig. Testicle perfusion predicts sperm quality and quantity. Fertil Steril 2007.

- TPU elevato ($p = 0.008$) e maggior numero di spermatozoi normali ($p = 0.003$)
- migliore qualità dello sperma e maggior numero di forme mobili ($p = 0.001$)



TPU = Tissue perfusion units

in biopsie eseguite su zone a maggiore vascolarizzazione rispetto a biopsie random

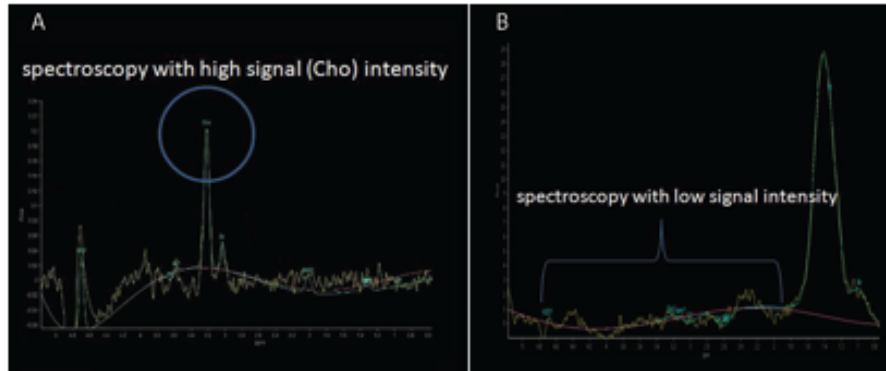


AFFINAMENTO DELLA TECNICA E PROSPETTIVE FUTURE

Testis spectroscopy may predict sperm retrieval rate in men with non-obstructive azoospermia undergoing micro-TESE: A pilot study

> J Turk Ger Gynecol Assoc. 2020 Jun 8;21(2):70-78. doi: 10.4274/jtgga.galenos.2019.2018.0154. Epub 2019 Oct 23.

Önder Çelik¹, Şafak Hatırnaz², Aynur Erşahin³, Alper Başbuğ⁴, Gonca Yetkin Yıldırım⁵, Vahit Özener⁶, Neslihan Gürpınar⁶, Sudenaz Çelik⁷, Nilüfer Çelik⁸, Tansu Küçük⁹, Cihat Ünlü⁹



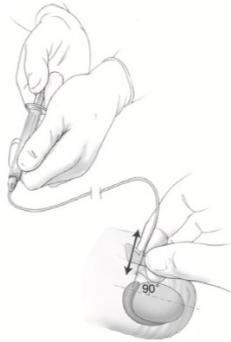
Elevati segnali di colina e creatina alla spettroscopia testicolare sono i migliori predittori positivi del recupero di sperma negli uomini NOA sottoposti a micro-TESE

Figure 5. Comparison of a spectroscopy with a high (A) and low (B) signal intensity. It is expected to be a healthy metabolic process in the testis of a man with high Cho peak (A). There is a high probability that the metabolic process is disturbed in the testis of a man with low signal. The first case belongs to a fertile case (A) and the second is a spectroscopy of a TESE negative case (B)

Cho: Choline, TESE: Testicular sperm extraction



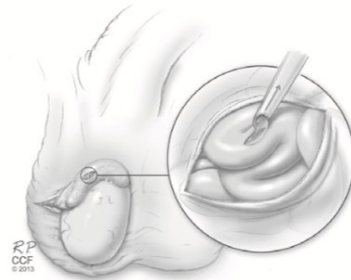AZOOSPERMIA OSTRUTTIVA (PESA – MESA)



Percutaneous epididymal sperm aspiration

- Semplice e mini-invasiva
- Procedura «cieca»
- Rischio di lesione vascolare

Tasso di successo 60%



Microsurgical epididymal sperm aspiration

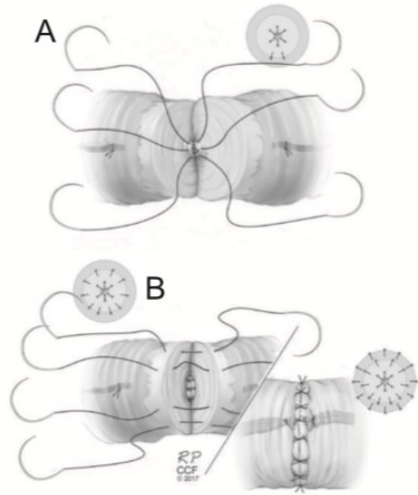
- Maggiore tasso di successo
- minore rischio di sanguinamento/ematoma
- Richiede l'utilizzo del microscopio
- Time consuming

Tasso di successo 90%

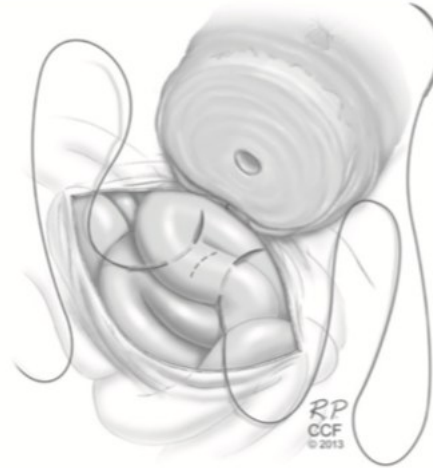

Esteves SC, Lee W, Benjamin DJ, Seol B, Verza S Jr, et al. Re-productive potential of men with obstructive azoospermia undergoing percutaneous sperm retrieval and intracytoplasmic sperm injection according to the cause of obstruction. J Urol. 2013;189:232-7

AZOOSPERMIA OSTRUTTIVA



Vaso-vasostomia



Vaso-epididimostomia

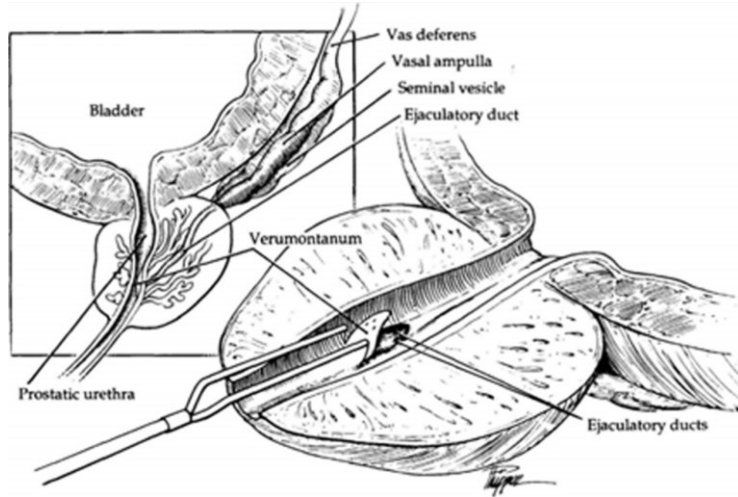
J Urol. 2004 Apr;171(4):1720-5.

Robotic microsurgical vasovasostomy and vasoepididymostomy: a prospective randomized study in a rat model.

Schiff J¹, Li PS, Goldstein M.



AZOOSPERMIA OSTRUTTIVA (TURED)



Transurethral resection of the ejaculatory ducts

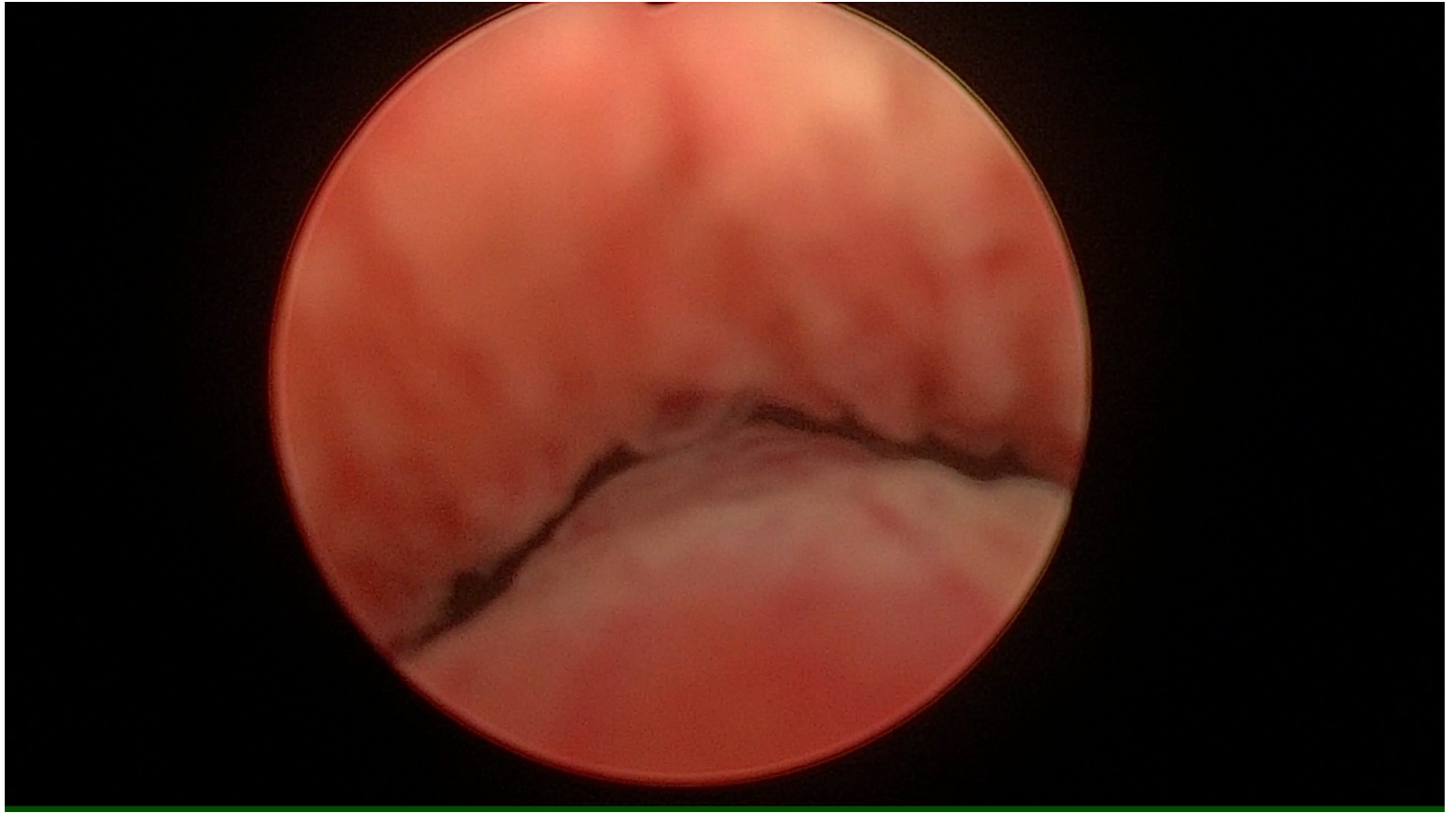
- Resezione endoscopica a livello del veru montanum
- Può essere eseguito con diverse fonti di energia
- Tasso di complicanze del 10%:
 - ematuria
 - reflusso urinario
 - epididimite

Miglioramento dei parametri seminali del 75% con un aumento del pregnancy rate del 30%



El-Assmy A, El-Tholoth H, Abouelkheir RT, Abou-El-Ghar ME. Transurethral resection of ejaculatory duct in infertile men: outcome and predictors of success. Int Urol Nephrol 2012;44:1623-30.

TURED



iaculazione ritardata eiaculazione retrograda
aneiaculazione anorgasmia

Table 15: Causes of delayed orgasm and anorgasmia [782]

Endocrine	Testosterone deficiency Hypothyroidism
Medications	Antidepressants Antipsychotics Opioids
Psychosexual causes	
Hyperstimulation	
Penile sensation loss	

Table 14: Aetiology of retrograde ejaculation [754]

Neurogenic	Spinal cord injury Cauda equina lesions Multiple sclerosis Autonomic neuropathy Retroperitoneal lymphadenectomy Sympathectomy or aortoiliac surgery Prostate, colorectal and anal surgery Parkinson's disease Diabetes mellitus Psychological/behavioural
Urethral	Ectopic ureterocele Urethral stricture Urethral valves or verumontanum hyperplasia Congenital dopamine β-hydroxylase deficiency
Pharmacological	Antihypertensives, thiazide diuretics α-1-Adrenoceptor antagonists Antipsychotics and antidepressants
Endocrine	Hypothyroidism Hypogonadism Hyperprolactinaemia
Bladder neck incompetence	Congenital defects/dysfunction of hemitrigone Bladder neck resection (transurethral resection of the prostate) Prostatectomy

Table 13: Aetiological causes of delayed ejaculation and anejaculation [739-742]

Ageing Men	Degeneration of penile afferent nerves inhibited ejaculation
Congenital	Mullerian duct cyst Wolfian duct abnormalities Prune Belly Syndrome Imperforate Anus Genetic abnormalities
Anatomic causes	Transurethral resection of prostate Bladder neck incision Circumcision Ejaculatory duct obstruction (can be congenital or acquired)
Neurogenic causes	Diabetic autonomic neuropathy Multiple sclerosis Spinal cord injury Radical prostatectomy Proctocolectomy Bilateral sympathectomy Abdominal aortic aneurysmectomy Para-aortic lymphadenectomy
Infective/Inflammation	Urethritis Genitourinary tuberculosis Schistosomiasis Prostatitis Orchitis
Endocrine	Hypogonadism Hypothyroidism Prolactin disorders Disorders of lipid metabolism
Medication	Antihypertensives; thiazide diuretics Alpha-adrenergic blockers Antipsychotics and antidepressants Alcohol Antiandrogens Ganglion blockers
Psychological	Anxiety Psychoses Acute psychological distress Relationship distress Psychosexual skill deficit Disconnect between arousal and sexual situations Masturbation style



EIACULAZIONE PRECOCE → evitamento rapporto sessuale

ALTERAZIONI SESSUALI

Impossibilità/difficoltà a iniziare o a portare a termine il rapporto sessuale

- Disfunzione erettile
- Alterazioni dell'eiaculazione (eiaculazione precoce, ritardata, dolorosa, retroeiaculazione, anorgasmia)
- Diminuzione del desiderio sessuale
- Alterazioni di forma e dimensione peniene (pene indovato, forme di accorciamento del pene congenite o acquisite, incurvamento penieno)
- Dismorfofobia (BDD, PDD)
- Condizioni psico-sociali di altra natura
- Situazioni sistemiche





Grazie per l'attenzione

